



The Pulmonary Vein Thrombosis Complicated with Diffuse Alveolar Hemorrhage and COVID-19: A Rare and Challenging Case Report

Mohammadreza Naghibi Sistani ¹, Ghazaleh Khademian ², Afsaneh Mohammadi ³, Mohammad Vojdanparast ⁴, Seyyed Masoud Sajjadi ³, Mahmood Hosseinzadeh Maleki ⁵, Hamidreza Reihani ⁶, *, Mohsen Yaghubi ⁷, **

¹ Pediatric and Congenital Cardiology Division, Department of Pediatric, Faculty of Medicine, Mashhad University of Medical Sciences, Mashhad, Iran

² Department of Anesthesiology, Razavi Hospital, Imam Reza International University, Mashhad, Iran

³ Department of Cardiology, Razavi Hospital, Imam Reza International University, Mashhad, Iran

⁴ Department of Cardiology, Cardiovascular Research Center, Imam Reza Hospital, Mashhad University of Medical Sciences, Mashhad, Iran

⁵ Department of Cardiac Surgery, Imam Reza Hospital, Mashhad University of Medical Sciences, Mashhad, Iran

⁶ Department of Emergency Medicine, Faculty of Medicine, Mashhad University of Medical Sciences, Mashhad, Iran

⁷ Department of Extra-corporeal Circulation (ECC), Razavi Hospital, Imam Reza International University, Mashhad, Iran

* **Corresponding Author:** Department of Emergency Medicine, Faculty of Medicine, Mashhad University of Medical Sciences, Mashhad, Iran. Email: reihanihr@mums.ac.ir

** **Corresponding Author:** Department of Extra-corporeal Circulation (ECC), Razavi Hospital, Imam Reza International University, Mashhad, Iran. Email: n.m.yaghubi@gmail.com

Received: 14 February, 2025; **Revised:** 18 April, 2025; **Accepted:** 27 April, 2025

Abstract

Introduction: Pulmonary vein thrombosis (PVT) is an extremely rare and potentially fatal condition. It is often recognized as a catastrophic event due to its life-threatening nature.

Case Presentation: A 12-year-old male patient was admitted to the emergency department with massive hemoptysis. Upon admission, his condition was critical, prompting immediate transfer to the intensive care unit (ICU). Given the progressive decline in his clinical and paraclinical parameters, mechanical ventilation was deemed necessary. Radiological evaluation using high-resolution computed tomography (lung HRCT) revealed evidence of pulmonary hemorrhage. Moreover, a thrombus located within the left superior pulmonary vein was detected. This diagnosis was further complicated by the patient's concomitant COVID-19 infection, which added layers of complexity to the management plan. Despite the complex critical presentation, he showed considerable improvement with a conservative therapeutic approach and careful monitoring. Eventually, he was discharged from the hospital in good health.

Conclusions: The indispensable role of a comprehensive approach led to the precise treatment of this challenging phenomenon. Evidence-based strategies can decrease the rate of morbidity and mortality associated with PVT.

Keywords: Pulmonary Veins, Thrombosis, COVID-19, Alveolar Hemorrhage

1. Introduction

Pulmonary vein thrombosis (PVT) is an infrequent and underdiagnosed condition in clinical practice, particularly in pediatric populations. Despite its infrequency, it is a critical and potentially life-threatening event (1). The rarity of this phenomenon can be attributed to the lung's extensive network of venous collateral vessels, which typically prevent obstruction.

However, certain pathological conditions can disrupt this balance, leading to PVT (2). Diagnosing PVT is often challenging and requires high clinical suspicion alongside advanced diagnostic imaging modalities (1, 3). In this report, we present the case of a pediatric male patient with diffuse alveolar hemorrhage (DAH) who was diagnosed with PVT in the context of a concurrent novel coronavirus (COVID-19) infection.

Copyright © 2025, Naghibi Sistani et al. This open-access article is available under the Creative Commons Attribution 4.0 (CC BY 4.0) International License (<https://creativecommons.org/licenses/by/4.0/>), which allows for unrestricted use, distribution, and reproduction in any medium, provided that the original work is properly cited.

How to Cite: Naghibi Sistani M, Khademian G, Mohammadi A, Vojdanparast M, Sajjadi S M, et al. The Pulmonary Vein Thrombosis Complicated with Diffuse Alveolar Hemorrhage and COVID-19: A Rare and Challenging Case Report. J Compr Ped. 2025; 16 (2): e160430. <https://doi.org/10.5812/jcp-160430>.

2. Case Presentation

2.1. Patient History

A 12-year-old male patient weighing 35 kg was admitted to the emergency department with complaints of severe shortness of breath, frequent coughing, and massive hemoptysis. His symptoms had worsened over the 12 hours prior to hospital arrival. During the initial history-taking, the patient reported prolonged exposure to his mother, who had probable seasonal influenza. He described a gradual onset of shortness of breath that abruptly worsened with a crescendo pattern, culminating in massive hemoptysis. His past medical history included anemia; however, he had no prior hospitalizations or medication use.

On admission, the patient's condition was critical. Hemodynamic parameters included a blood pressure of 88/45 mmHg, heart rate of 152 bpm, respiratory rate of 42 breaths/min, and oxygen saturation of 74% at rest as measured by a finger pulse oximeter. He was febrile with a core temperature of 38.9°C.

2.2. Diagnostic Work-up and Management Strategy

Considering his critical condition, the patient was immediately transferred to the intensive care unit (ICU) for close monitoring and advanced care. In the ICU, he was started on high-flow nasal oxygen therapy. Arterial blood gas analysis revealed severe acute respiratory acidosis. Within 20 minutes, his respiratory effort became insufficient. He experienced massive hemoptysis, a decreased level of consciousness, and an inability to clear airway secretions. Based on his deteriorating ABG parameters and clinical instability, invasive mechanical ventilation was initiated.

Initial portable chest radiography (anteroposterior view) demonstrated significant bilateral diffuse infiltrates in the upper and lower lobes consistent with pulmonary involvement. However, no evidence of cardiovascular abnormalities or pleural effusion was noted. The costophrenic angles were sharp, with no signs of pleural effusion ([Figure 1](#)).

Given the patient's febrile state upon arrival and the exclusion of an infectious etiology, empirical broad-spectrum antibiotics were initiated. He received meropenem (40 mg/kg q8h) and ciprofloxacin (5 mg/kg q12h). Before starting antibiotics, BACTEC blood and urine cultures were obtained, both of which returned

negative after 48 hours. A viral panel was also performed for influenza A and B, respiratory syncytial virus, and SARS-CoV-2.

Corticosteroid therapy was initiated after endotracheal intubation with methylprednisolone administered intravenously at 0.5 mg/kg q12h. Laboratory results revealed mild hematuria and glycosuria alongside granular casts in the urine. Procalcitonin levels were elevated (10.21 ng/mL), indicating a high risk of systemic inflammation and organ dysfunction. Hematological parameters on the first day are provided in [Table 1](#).

D-dimer levels were markedly elevated (3424 ng/FEU mL), prompting a cardiac evaluation. Serologic studies, including the purified protein derivative (PPD) skin test and the Coombs Wright test, returned negative results. Bedside transthoracic echocardiography revealed a preserved left ventricular ejection fraction (about 50% by visual estimation) with no evidence of pulmonary thromboembolism, pericardial effusion, regional wall motion abnormality, or significant valvular heart disease. However, the mean pulmonary artery pressure was elevated (28 mmHg). Electrocardiographic findings showed sinus narrow complex tachycardia without evidence of P-wave abnormalities, heart block, or QTc prolongation.

Further autoimmune and inflammatory testing revealed negative results for cytoplasmic antineutrophil cytoplasmic antibodies (C-ANCA), perinuclear antineutrophil cytoplasmic antibodies (P-ANCA), anti-cyclic citrullinated peptide (anti-CCP), antinuclear antibodies (ANA), and the native double-stranded DNA antibody (anti-dsDNA). The patient underwent high-resolution computed tomography (HRCT) of the chest without contrast, which demonstrated significant ground-glass opacities, bronchiectasis, and interlobular septal thickening, particularly in the bilateral upper lobes, consistent with pulmonary hemorrhage ([Figure 2](#)). No pleural effusion or mediastinal lymphadenopathy was found.

Subsequent contrast-enhanced chest CT revealed a thrombus in the left superior pulmonary vein ([Figure 3](#)). The coagulation profile was within normal limits. Considering these findings, enoxaparin (4000 mg, twice daily) was initially prescribed to minimize the risk of embolization. This approach was followed by warfarin (2.5 mg daily) for systemic anticoagulation. Coagulation parameters were monitored daily to balance the risks of

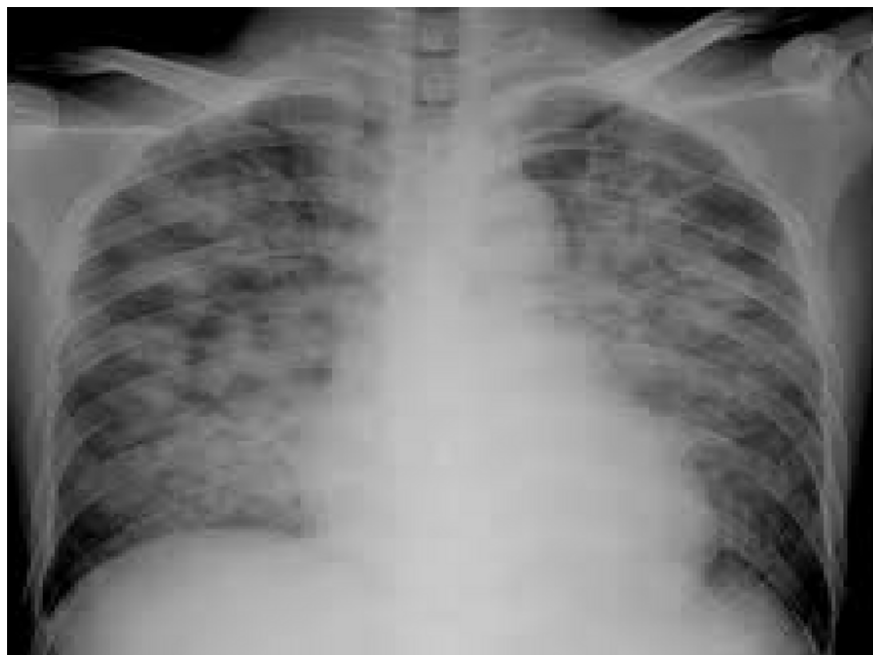

Figure 1. Chest X-ray in AP view demonstrated diffuse bilateral infiltration, both in upper and lower lobes, without any evidence of pleural effusion.

Table 1. Hematological Assessment of the Patient on the First Day of Hospitalization

Laboratory Test	Result	Laboratory Test	Result
Hemoglobin	8.5 g/dL	ESR	34 mm/h
Hematocrit	24.3%	hs-CRP	119.54 mg/L
MCV	56.8 fL	PT	11.0 s
MCH	14.9 p.g	PTT	25.4 s
Fibrinogen	2450 mg/dL	INR	1.00
FDP	5 < FDP < 20	Protein-C	91 IU/dL
D-dimer	3424 ng/FEU mL	Protein-S	85 IU/dL

Abbreviations: MCV, mean corpuscular volume; MCH, mean corpuscular hemoglobin; FDP, fibrinogen degradation product; ESR, erythrocyte sedimentation rate; PT, prothrombin time; PTT, partial thromboplastin time; INR, international normalized ratio.

anticoagulation therapy and ongoing diffuse alveolar hemorrhage.

On the second day of ICU admission, the patient tested positive for COVID-19. Standard isolation precautions and a COVID-19 management protocol were implemented, including supportive care and medication. Fourteen days after mechanical ventilation, improvement in clinical and ABG parameters allowed the development of a weaning plan. The following day, the patient was successfully weaned from mechanical

ventilation, and extubation was performed after 18 hours.

Subsequently, bedside fiberoptic bronchoscopy assessed the alveolar status post-hemorrhage for potential tracheal microbial infection. Bronchoalveolar lavage (BAL) samples revealed hemosiderosis deposition in alveoli consistent with diffuse alveolar hemorrhage. No bacterial, fungal, viral, or pneumocystis carinii infections were identified. Corticosteroid therapy was tapered, and antibiotics were gradually discontinued.

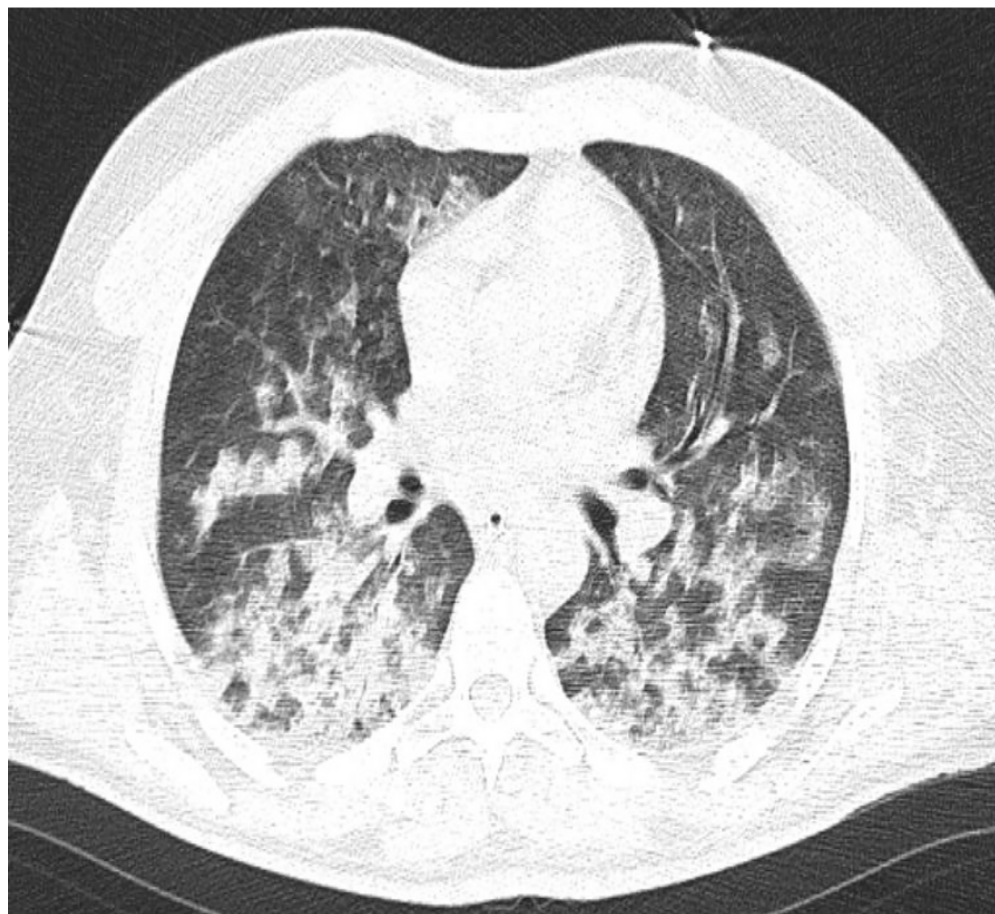


Figure 2. Chest high-resolution computed tomography (HRCT), without contrast, in an inspiration period, showed interlobular septal thickening and bronchiectasis in both lungs more prominent in bilateral upper lobes.

2.3. Follow-up Treatment and Care Strategies

A follow-up chest X-ray showed significant improvement with a reduction in the bilateral opacities (Figure 4). Oxygen therapy was continued via a simple face mask at 8 L/min, later transitioned to a nasal cannula delivering 4 L/min. The patient demonstrated steady clinical improvement and was transferred to the post-ICU in stable condition. Four days later, he was discharged with appropriate advice to address his anemia and avoid exposure to pulmonary irritants.

Warfarin was reduced to 1.25 mg daily, guided by PT and INR measurements performed weekly after discharge. A follow-up echocardiography appointment was recommended three months post-discharge to

evaluate cardiac function, particularly pulmonary artery pressure.

3. Discussion

Pulmonary vein thrombosis is an extremely rare condition most often associated with significant pulmonary or cardiac events such as major pulmonary surgery (e.g., transplantation), lung malignancies, chest trauma, arteriovenous malformations, mitral stenosis, radiofrequency catheter ablation for atrial fibrillation, sclerosing mediastinitis, and atrial myxoma (4-6). However, in rare instances, no underlying cause is identified (3). In our patient's case, there was no history of comorbidities or prior hospitalizations, adding to the complexity of the diagnosis.

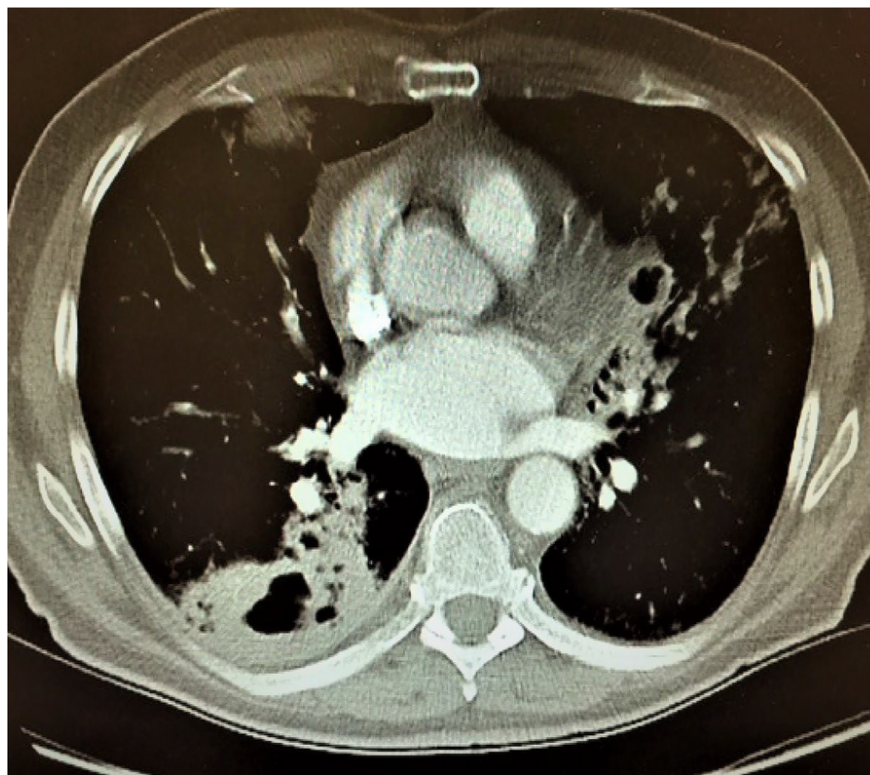


Figure 3. The high-resolution computed tomography (HRCT) after intravenous contrast injection in the late phase revealed a thrombus in the left superior pulmonary vein.

The PVT can be asymptomatic or present with nonspecific symptoms, including pleuritic chest pain, cough, fever, shortness of breath, and hemoptysis. It is not uncommon for PVT to be misdiagnosed as a pulmonary embolism due to overlapping clinical presentations. Additionally, in our case DAH, a severe and potentially life-threatening condition that results from injury to the pulmonary microcirculation, further confounded the diagnosis. The DAH is characterized by hemoptysis, anemia, diffuse lung infiltrates, and acute respiratory failure (7, 8). The simultaneous presence of PVT and DAH in this patient made it challenging to determine whether DAH or PVT was the primary cause of specific symptoms, as both conditions can share similar clinical manifestations.

The underlying pathophysiology of symptoms in PVT likely involves elevated pulmonary venous pressure, which may lead to secondary increases in pulmonary arterial pressure (3). In this case, echocardiography revealed elevated mean pulmonary arterial pressure

(MPAP), which supported PVT as a contributing factor to the patient's symptoms. Previous studies have reported normal pulmonary artery pressures in patients with DAH (7), further suggesting that PVT played a pivotal role in the clinical manifestations observed in this patient.

Laboratory findings in our patient revealed a normal coagulation state, as supported by normal protein C and protein S levels, ruling out deficiencies as the cause of thrombosis. Other studies have highlighted the importance of hypercoagulable states, such as protein C and protein S deficiencies, in developing thrombotic events, including PVT (9-11). While these deficiencies can generally be excluded with normal test results, additional factors may have contributed to thrombus formation (12). One possible explanation is inflammation-mediated platelet activation, which, combined with endothelial damage, may lead to fibrin deposition and thrombus formation (13). Viral infections, including COVID-19, have well-established

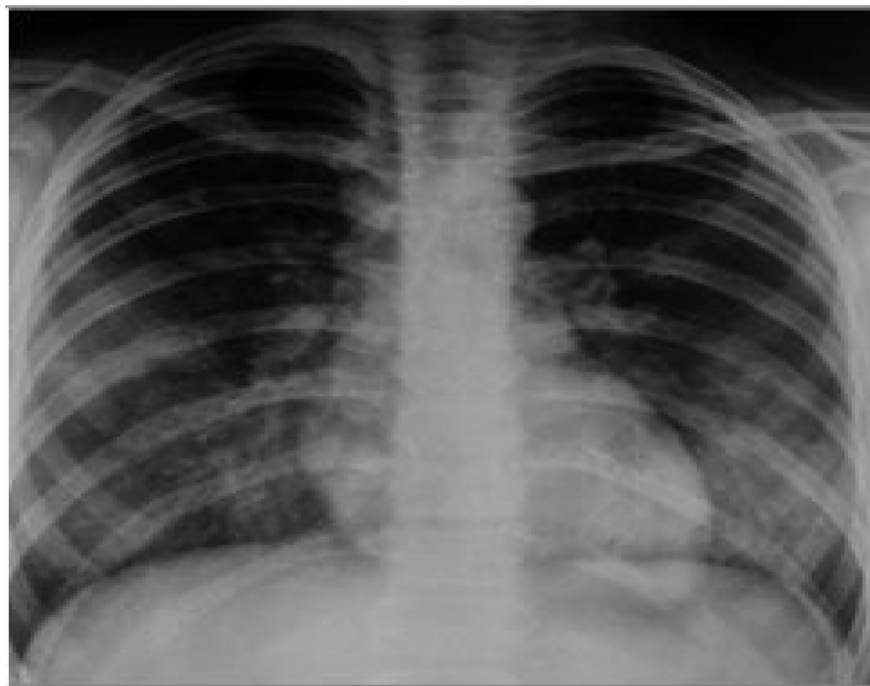

Figure 4. Chest X-ray in AP view after mechanical ventilation weaning demonstrated a significant improvement in diffuse opacities of both lungs.

links to coagulopathy and alterations in the hemostatic balance, resulting in both hemorrhagic and thrombotic complications (14). For example, the influenza virus has been shown to induce platelet aggregation, pulmonary microvascular thrombosis, endothelial dysfunction, and an exaggerated inflammatory response (15, 16). Similarly, the so-called "cytokine storm", triggered by severe COVID-19, is a major driver of acute respiratory distress and pulmonary complications (17). Probably, the diffuse alveolar hemorrhage and subsequent PVT in our patient were precipitated by the proinflammatory and prothrombotic effects of COVID-19.

Diagnosing PVT is notably challenging due to its nonspecific symptoms. Accurate identification often requires a combination of advanced imaging modalities, such as HRCT with contrast, transthoracic echocardiography (TTE), transesophageal echocardiography (TEE), or magnetic resonance imaging (MRI) (18-20). Our patient's HRCT with intravenous contrast proved instrumental in identifying the thrombus within the left superior pulmonary vein. The delayed phase of contrast imaging

was beneficial in reducing motion-related artifacts. Transthoracic echocardiography revealed elevated MPAP but lacked other specific findings. Based on the latest guidelines from the American Society of TEE, it was not performed in this case (21).

Management of PVT should be tailored to the underlying pathology and often includes antibiotics (for infectious causes), anticoagulation, or surgical intervention (1). In our patient, empirical antibiotic therapy with meropenem and ciprofloxacin was initially administered to prevent secondary lung infections despite the absence of an identifiable bacterial source. Anticoagulation therapy with low molecular weight heparin (enoxaparin) was initiated to minimize the risk of embolization, later transitioning to warfarin for long-term systemic anticoagulation to dissolve the thrombus. This approach was selected in light of the patient's massive hemoptysis, aiming to reduce hemorrhagic recurrence while managing thrombotic complications. Similar protocols for managing DAH with careful anticoagulation have demonstrated successful outcomes in other studies (10).

The co-occurrence of COVID-19 in this patient added significant complexity to the clinical course, as the hyperinflammatory state compounded the risks of both hemorrhagic and thrombotic complications. This case underscores the importance of a multidisciplinary approach for early recognition, accurate diagnosis, and precise, aggressive treatment of PVT. Managing patients with coexisting conditions like COVID-19 requires meticulous attention and a holistic strategy to optimize outcomes.

In conclusion, the interplay between COVID-19, diffuse alveolar hemorrhage, and PVT presents unique diagnostic and therapeutic challenges. Early and accurate identification of rare conditions like PVT, guided by advanced imaging and a multidisciplinary care strategy, is paramount to reducing morbidity and mortality in such complex cases.

Footnotes

Authors' Contribution: M. R. N. S.: Contributed to the conception of the work, revising the draft, approving the final version of the manuscript, and agreeing on all aspects of the work; G. K., A. M., and M. V.: Contributed to the critical revision, and approval of the final version of the manuscript; M. S. and M. H. M: Contributed to acquiring data, drafting the manuscript, and approving the final version; H. R. and M. Y: Contributed to the conception and design of the study, data interpretation, drafting of the manuscript and critical revision, and approval of final version.

Conflict of Interests Statement: The authors have no conflict of interests.

Data Availability: The dataset presented in the study is available on request from the corresponding author during submission or after its publication.

Ethical Approval: The Mashhad University of Medical Sciences ethics committee approved the study protocol with the number of [IR.MUMS.REC.1399.082](#) , which complies with the Declaration of Helsinki.

Funding/Support: The authors declared no funding for the study.

Informed Consent: Informed consent was obtained from the patient's parents.

References

1. Chaaya G, Vishnubhotla P. Pulmonary Vein Thrombosis: A Recent Systematic Review. *Cureus*. 2017;9(1). e993. <https://doi.org/10.7759/cureus.993>.
2. Cavaco RA, Kaul S, Chapman T, Casaretti R, Philips B, Rhodes A, et al. Idiopathic pulmonary fibrosis associated with pulmonary vein thrombosis: a case report. *Cases J*. 2009;2:9156. [PubMed ID: 20062673]. [PubMed Central ID: PMC2803953]. <https://doi.org/10.1186/1757-1626-2-9156>.
3. Rana MA, Tilbury N, Kumar Y, Ahmad H, Naser K, Mady AF, et al. Idiopathic Pulmonary Vein Thrombus Extending into Left Atrium: A Case Report and Review of the Literature. *Case Rep Med*. 2016;2016:3528393. [PubMed ID: 27274732]. [PubMed Central ID: PMC4871951]. <https://doi.org/10.1155/2016/3528393>.
4. Stein PD, Denier JE, Goodman LR, Matta F, Hughes MJ. Pulmonary vein thrombosis in patients with medical risk factors. *Radiol Case Rep*. 2018;13(6):1170-3. [PubMed ID: 30233753]. [PubMed Central ID: PMC6140413]. <https://doi.org/10.1016/j.radcr.2018.07.031>.
5. Asai K, Mochizuki T, Iizuka S, Momiki S, Suzuki K. Pulmonary vein stump thrombus: an early complication following upper division segmentectomy of the left lung. *Gen Thorac Cardiovasc Surg*. 2014;62(4):244-7. [PubMed ID: 23462958]. <https://doi.org/10.1007/s11748-013-0229-1>.
6. Ghasemi R, Ghanei-Motlagh F, Nazari S, Yaghubi M. Huge mass in right side of the heart: A rare case report. *ARYA Atherosclerosis J*. 2017;12(6):291-4.
7. Yaghubi M, Valaei M, Ghasemi R, Hosseinzadeh Maleki M, Rezaei S, Kakhki S. Rapid Successful Management of Diffuse Alveolar Hemorrhage as the Primary Presentation of Chlorine Gas Inhalation: A Rare Case Report. *Acta Medica Iranica*. 2021;59(10):617-20. <https://doi.org/10.18502/acta.v59i10.7770>.
8. Moodi F, Hosseinzadeh Maleki M, Mohammadi A, Ghasemi R, Yaghubi M. The Left Ventricular Intra-Myocardial Dissecting Hematoma Presented as a Rare Complication of the Neglected Myocardial Infarction. *Acta Medica Iranica*. 2024;61(10):635-8. <https://doi.org/10.18502/acta.v61i10.15665>.
9. Barreiro TJ, Kollipara VK, Gemmel DJ. Idiopathic pulmonary vein thrombosis? *Respirol Case Rep*. 2018;6(1). e00277. [PubMed ID: 29321923]. [PubMed Central ID: PMC5757585]. <https://doi.org/10.1002/rcr2.277>.
10. Saoraya J, Inboriboon PC. Pulmonary vein thrombosis associated with a large hiatal hernia. *J Emerg Med*. 2013;44(3):e299-301. [PubMed ID: 23218196]. <https://doi.org/10.1016/j.jemermed.2012.09.029>.
11. Akiode O, Prakash G. Pulmonary vein thrombosis associated with metastatic carcinoma. *Fed Pract*. 2014;31(12):26-8.
12. Minuk L, Lazo-Langner A, Kovacs J, Robbins M, Morrow B, Kovacs M. Normal levels of protein C and protein S tested in the acute phase of a venous thromboembolic event are not falsely elevated. *Thromb J*. 2010;8:10. [PubMed ID: 20482785]. [PubMed Central ID: PMC2887791]. <https://doi.org/10.1186/1477-9560-8-10>.
13. Beristain-Covarrubias N, Perez-Toledo M, Thomas MR, Henderson IR, Watson SP, Cunningham AF. Understanding Infection-Induced Thrombosis: Lessons Learned From Animal Models. *Front Immunol*. 2019;10:2569. [PubMed ID: 31749809]. [PubMed Central ID: PMC6848062]. <https://doi.org/10.3389/fimmu.2019.02569>.
14. Yang Y, Tang H. Aberrant coagulation causes a hyper-inflammatory response in severe influenza pneumonia. *Cell Mol Immunol*.

- 2016;**13**(4):432-42. [PubMed ID: [27041635](#)]. [PubMed Central ID: [PMC4947825](#)]. <https://doi.org/10.1038/cmi.2016.1>.
15. Short KR, Kroeze E, Fouchier RAM, Kuiken T. Pathogenesis of influenza-induced acute respiratory distress syndrome. *Lancet Infect Dis*. 2014;**14**(1):57-69. [PubMed ID: [24239327](#)]. [https://doi.org/10.1016/S1473-3099\(13\)70286-X](https://doi.org/10.1016/S1473-3099(13)70286-X).
 16. Le VB, Schneider JG, Boergeling Y, Berri F, Ducatez M, Guerin JL, et al. Platelet activation and aggregation promote lung inflammation and influenza virus pathogenesis. *Am J Respir Crit Care Med*. 2015;**191**(7):804-19. [PubMed ID: [25664391](#)]. <https://doi.org/10.1164/rccm.201406-1031OC>.
 17. Hosseinzadeh Maleki M, Younessi Heravi MA, Ghasemi R, Gharaee R, Yaghubi M. Effect of Body Position Change and Vital Signals on Endotracheal Tube Cuff Pressure Variations. *Evidence Based Care*. 2022;**12**(1):14-22. <https://doi.org/10.22038/ebcj.2021.60071.2560>.
 18. Malm B, Hull S, Jadbabaie F. Left upper pulmonary vein thrombus in a patient with atrial fibrillation and prior lobectomy. *Am J Med*. 2014;**127**(11):e7-8. [PubMed ID: [25132349](#)]. <https://doi.org/10.1016/j.amjmed.2014.07.029>.
 19. Porres DV, Morenza OP, Pallisa E, Roque A, Andreu J, Martinez M. Learning from the pulmonary veins. *Radiographics*. 2013;**33**(4):999-1022. [PubMed ID: [23842969](#)]. <https://doi.org/10.1148/rg.334125043>.
 20. Kinsella JA, Maccarthy AJ, Kiernan TJ, Moore DP, McDermott RS, McCabe DJ. Transesophageal Echocardiographically-Confirmed Pulmonary Vein Thrombosis in Association with Posterior Circulation Infarction. *Case Rep Neurol*. 2010;**2**(1):24-31. [PubMed ID: [20689631](#)]. [PubMed Central ID: [PMC2914368](#)]. <https://doi.org/10.1159/000313599>.
 21. Kirkpatrick JN, Grimm R, Johri AM, Kimura BJ, Kort S, Labovitz AJ, et al. Recommendations for Echocardiography Laboratories Participating in Cardiac Point of Care Cardiac Ultrasound (POCUS) and Critical Care Echocardiography Training: Report from the American Society of Echocardiography. *J Am Soc Echocardiogr*. 2020;**33**(4):409-422 e4. [PubMed ID: [32122742](#)]. <https://doi.org/10.1016/j.echo.2020.01.008>.